Case reports of Erysipelas in two free-ranging dolphins (*Tursiops aduncus* and *Neophocaena phocaenoides*) stranded along the Gulf of Thailand

Pimchanok Prachamkhai[1], Thanapan Chomchuen[2], Oranee Jongkolpath[2], Watchara Sakornwimon[1], Autthaporn Jeenpun[3], Manakorn Sukmak[4]

Marine and coastal resources research center, Central Gulf of Thailand, Department of Marine and Coastal Resources[1], Marine and coastal resources research center, Eastern Gulf of Thailand, Department of Marine and Coastal Resources[2],
Veterinary research and development center (upper southern region), Department of Livestock Development[3]. Kamphaengsaen Veterinary Diagnostic Center (KVDC), Faculty of Veterinary Medicine, Kasetseart University[4]

ABSTRACT

Erysipelas is a bacterial infection that causes by *Erysipilothrix rhusiopathiae*. This disease is known as diamond skin disease that may affect a wide range of animals such as pigs, turkeys, and hens. In 2020, two emaciated dolphins stranded in Gulf of Thailand including a bottlenose dolphin (*Tursiops aduncus*) and a finless porpoise (*Neophocaena phocaenoides*). The bottlenose dolphin stranded alive with non-specific signs and weakness, while the dead finless porpoise showed the sign of cutaneous form as rhomboid-shaped skin lesions. Generalized lymphadenopathy, pulmonary congestion and frothy exudate in trachea were compatible macroscopic lesions, and ascites were found in bottlenose dolphin. Both cases were collected tissue samples for bacterial isolation and PCR sequencing, the analysis yielded *Erysipilothrix rhusiopathiae* which can be found in various species and important occupational zoonosis. This is the first report of Erysipelas infection in wild dolphins in Thailand.

INTRODUCTION

Erysipilothrix rhusiopathiae causes the disease known as erysipelas that is gram positive, facultative anaerobic bacillus. It is widespread in the nature include the ocean and has been reported as a commensal or a pathogen in various vertebrate and invertebrate species such as fish[1], swine[2], turkeys[3], sheep[4], ticks, flies and mites[5]. In addition, It has been reported in marine mammal infection for six decades including captive and free-ranging cetaceans such as captive spotted dolphin and porpoises[6], captive killer whale[7], free-ranging bottlenose dolphin[8]. Besides animal infection, the risk of human infection with erysipelas is related to the exposure opportunity to the organism. Most human cases are related to occupational exposure by contact with contaminated animals, especially while handling fish, their products, their wastes, or soil[5]. Those at greatest risk are fishermen, butchers, slaughterhouse workers, veterinarians and housewives. Three forms of disease caused by E. *rhusiopathiae* infection have been described in humans: a localized cutaneous form, a generalized cutaneous form, and a septicemic form, which is associated with endocarditis. If untreated, the septicemic form often results in death in humans[5] and animals[9]. The pathognomonic sign of erysipelas in many species is the presence of diamond-shaped skin lesions[5]. In cetaceans, the lesions appear as gray, elevated rhomboid plaques with well-defined edges that occur over the entire body[9, 10, 11, 12, 13]. However, this zoonotic disease has been never reported in cetacean species of Thai waters, the present report describes gross lesions and diagnostic methods as bacterial culture and molecular analysis of the first reported cases.

METHODOLOGY

Animals

Two dolphins stranded in gulf of Thailand with poor body condition including one bottlenose dolphin and one finless porpoise. On 21 May 2020, a juvenile female bottlenose dolphin stranded alive on Mae Pim cape, Rayong province. The dolphin was 164 cm in total length with 2/5 body condition score. It was able to swim and the local stranding network tried to release it back. The dolphin showed sign of seizure and died within few minutes during transportation. Another 139 cm long, adult male dolphin was finless porpoise found dead at Thung Sang beach, Chumphon province on 25 August 2020. The carcass had 2/5 decomposition code with emaciated condition.

Necropsy and tissue sampling

Both dolphins were performed standard necropsy, measured, weighed, photographed organs and collected tissue samples by DMCR veterinarians for diagnosis.

Bacterial identification

Samples of brain, kidney, lung, skin and blood were collected for microbiology, then cultured with standard method for bacterial isolation and biochemical identification. Those collected tissues were put on blood agar and incubated under aerobically and anaerobic conditions for 48 h at 37˚ C. Isolates were identified using the commercial API Coryne system.

PCR and sequencing

The samples were analyzed by PCR and sequencing. The DNA extraction was performed using 20 mg of formalin-fixed tissue. The tissue was applied to digest using proteinase K (0.5 mg/ml) at 65 C for 12 hours then subjected to DNA extraction using modified phenol-chloroform method[14]. The 16s-Erysipelotrix specific primers MO101 (5'-AGATGCCATAGAAACTGGTA-3') and MO102 (5'-CTGATCCGCCATAACTA-3') were used to identify the pathogen[15]. The PCR reaction was performed using Phusion High-fidelity DNA polymerase (Finnzymes) following the manufacturer's protocol. PCR amplicons were observed using 1.5% agarose gel electrophoresis then were excised and purified using the MinElute Gel Extraction Kit (QiagenÒ), following the manufacturer's recommendations. Sequencing was per- formed in both directions, employing the BigDye Terminator version 1.1 Cycle Sequencing Kit (Applied Biosystems), on a 3730 DNA Analyzer (Applied Biosystems). Purified PCR products were sent for sequencing to the First Base Labora- tory, Shah Alam, Malaysia. The obtained sequence was then blasted to GenBank to verify the type of pathogen.

.

RESULTS AND DISCUSSION

Macroscopic findings

Complete necropsy of the bottlenose dolphin revealed multifocal cutaneous erythema of right lateral trunk especially thoracic area and peduncle, focal white plaque on tongue and oral cavity, increased corneal opacity of both eyes, generalized pulmonary edema with moderate frothy exudate along trachea, multifocal white spot in liver, erythematous inflammation of main stomach, straw color fluid in abdominal cavity and markedly generalized lymphadenopathy. Moreover, trematodes were found in pylorus which are suspected to be Gastric *Braunina cordiformis*.

In finless porpoise, there were multifocal cutaneous diamond-shaped lesions with well-defined edges on both side of body surface, pulmonary congestion, generalized lymphadenopathy especially for pulmonary lymph nodes, yellow foci in hepatic parenchyma, gastric ulcer and red-tinged urine.

Bacterial identification

Gram-positive, facultative anaerobic bacilli were isolated from tissue samples. Isolates were identified as *Erysipelothrix rhusiopathiae* by using the commercial strip 'API Coryne system', then the isolates of both dolphins were confirmed by PCR and sequencing again.

The cause of death in two animals was determined as Erysipelas infection in different forms. The bottlenose dolphin had peracute−acute septicemic form with non-specific signs, eg. anorexia, lethargy, while the finless porpoise displayed significant signs of chronic dermatologic form. Their gross lesions and bacteriology results were compatible with those infected cetaceans reports[6, 10, 11]. From database of marine mammal stranding in Thai waters between 2015 and 2021, there was only a dolphin found diamond-skin lesions as this finless porpoise. Dermatological form affected animals are rarely reported in free-ranging individuals[8], this indicate that these animals are self-limited. Consequently, the proportion of dolphins with acute septicemic phase could be the majority of stranded animals which have E. *rhusiopathiae* infection[16]. Since most stranded carcasses have presented in moderate to advance decomposed condition due to temperate zone, no case of Erysipelas has been confirmed. The undeniable environmental factors is one of primary challenges in disease surveillance in Thailand.

In conclusion, these two cases are the first case report of confirmed E. *rhusiopathiae* infection in free-ranging dolphins of Thai waters. Furthermore, systematic disease surveillance should be planed and performed to access prevalence of this importantly zoonotic disease.

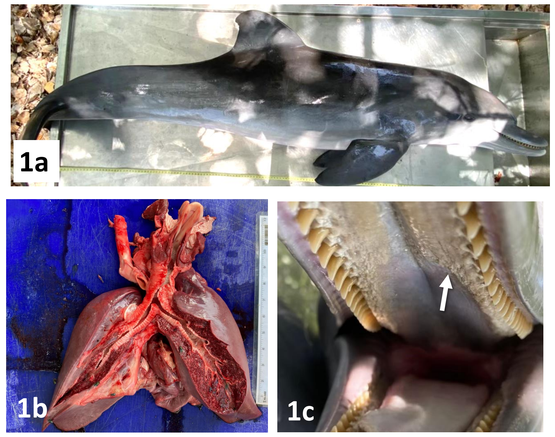

Figure 1. Bottlenose dolphin; external appearance showed poor body condition (1a), gross finding of lung found pneumonia (pulmonary consolidation) with frothy exudate in trachea (1b), focal white irregular plaque (white arrow) on tongue and oral cavity (1c)

Figure 2. Finless porpoise; external appearance showed emaciated condition (2a), rhomboid-shaped skin lesions on lateral trunk (2b), pulmonary congestion with pulmonary lymphadenopathy (white arrow) (2c)

REFERENCES

1. Lehane L and Rawlin GT. Topically acquired bacterial zoonoses from fish: a review. Medical Journal of Australia. 2000; 173(5): 256-259.
2. Bender JS, Shen HG, Irwin CK, Schwartz KJ, and Opriesnig T. Characterization of Erysipelothrix Species Isolates from Clinically Affected Pigs, Environmental Samples, and Vaccine Strains from Six Recent Swine Erysipelas Outbreaks in the United States. Clin Vaccine Immunol. 2010; 17(10): 1605–1611.
3. Silva AP, Cooper G, Blakey J, Jerry C, Shivaprasad HL, Stoute S. Retrospective Summary of Erysipelothrix rhusiopathiae Diagnosed in Avian Species in California (2000-19). 2020; 64(4):499-506.
4. Ersdal C, Jørgensen HJ, Lie K-I. Acute and Chronic Erysipelothrix rhusiopathiae Infection in Lambs. 2015 ;52(4):635-43.
5. Wang QN, Chang BJ, and Riley TV. Erysipelothrix rhusiopathiae. Vet. Microbiol. 2010; 140: 405–417.
6. Seibold HR and Neal JE. Erysipelothrix septicemia in the porpoise. Javma-journal of The American Veterinary Medical Association. 1956; 128: 537.
7. Bossart GD and Eimstad EA. Erysipelothrix Vesicular Glossitis in a Killer Whale (Orcinus orca). The Journal of Zoo Animal Medicine. 1988; 19(1/2): 42–47.
8. Melero M, RUBIO-GUERRI C, Picazo JLC, Arbelo M, Vela A, Garcia PD, Sierra E, Domínguez RL, Sánchez-Vizcaíno J. First case of erysipelas in a free-ranging bottlenose dolphin (Tursiops truncatus) stranded in the Mediterranean Sea. Diseases of aquatic organisms. 2011; 97: 167-70.
9. Suer L and Vedros NA. Erysipelothrix rhusiopathiae. I. Isolation and characterization from pinnipeds and bite/ abrasion wounds in humans. Diseases of Aquatic Organisms. 1988; 5: 1-5.
10. Thurman GD, Downes SJ, Fothergill MB, Goodwin NM, Hegarty MM. Diagnosis and successful treatment of subacute erysipelas in a captive dolphin. J S Afr Vet Assoc. 1983; 54: 193−200.
11. Kinsel MJ, Boehm JR, Harris B, Murnane RD (1997) Fatal Erysipelothrix rhusiopathiae septicaemia in a captive Pacific white-sided dolphin. J Zoo Wildl Med. 1997; 28: 494−497.
12. Dunn JL, Buck JD, Robeck TR. Bacterial diseases of cetaceans and pinnipeds. In: Dierauf LA, Gulland FMD (eds) Handbook of marine mammal medicine: health, disease and rehabilitation, 2nd edn. CRC Press. 2001; Boca Raton, FL, 312−319
13. Boseret G, Jauniaux T, and Mainil J. Erysipelothrix rhusiopathiae infection in stranded harbour porpoise and harbour seal. In: Erken AHM, Dorrenstein GM, Dollinger P (eds) Proc 2002 Eur Assoc Zoo Wildl Vet Annu Meet, Van Setten Kwadraat, Houten. 2002: 15–17.
14. Nelson JN and Krawetz SA. Purification of cloned and genomic DNA by guanidine thiocyanate/isobutyl alcohol fractionation. Analytical Biochemistry. 1992; 207(1):197-201.
15. Boerner L, Nevis KR, Hinckley LS, Weber ES, Frasca S Jr. Erysipelothrix septicemia in a little blue penguin (Eudyptula minor). J Vet Diagn Invest. 2004 ;16(2): 145-9.
16. Díaz-Delgado J, Arbelo M, Sierra E, Vela A, Domínguez M, Paz Y, Andrada M, Domínguez L, and Fernández A. Fatal Erysipelothrix rhusiopathiae septicemia in two Atlantic dolphins (Stenella frontalis and Tursiops truncatus). Dis Aquat Organ. 2015;116(1):75-81.